

HISTOLOGICAL CHANGES IN REPTILEAN SPINAL CORD TRANSECTION : CORRELATION WITH FUNCTIONAL RECOVERY

VINDOD KUMAR SRIVASTAVA*, VEENA MAHESHWARI,**
S. P. TYAGI* AND SHAUKAT ALI***

*Neurosurgical Unit and Departments of
Pathology and *Anatomy,
J. N. Medical College,
A.M.U., Aligarh - 202 002

(Received on May 4, 1993)

Abstract: The study of spinal cord regeneration in the phylogenetic scale is likely to help us in the understanding of the problem in the human situation. After spinal transection in lizards, histological changes in the spinal cord were studied and correlated with functional recovery. Some changes in spinal cord, suggestive of regeneration between the two stumps were observed. The recovery of function did not appear to be dependent on synaptic continuity.

Key words: reptilean spinal cord regeneration histological *Calotus calotus*

INTRODUCTION

Spinal cord injury is one of the most dismal chapters in medicine. Various approaches for recovery from its baneful effects have been tried with little success. One of the approaches in the study of spinal cord regeneration (SCR) in submammalian species is to develop a regenerating model (1). It was with this in view that SCR was studied in garden lizards (*Calotus calotus*). Functional recovery has been successfully demonstrated in these animals following mid-dorsal transection of the spinal cord (2). The present study is designed to analyse the histological profile of SCR in the same material.

METHODS

Thirty garden lizards were subjected to middorsal spinal transection. The operative procedure has been described elsewhere (2). The animals were fed and kept alive. Functional recovery was studied as the ability of the animal to hold itself against a vertical

wire mesh and the ability to walk and run normally (2). Skin and muscle were excised to expose the operated site before placing the animal in 10% formalin immediately after death. After one week the vertebral tissue with spinal cord *in situ* was dissected 1" above and below the operated site and it was placed in 10% formalin.

Attempts were made to dissect the cord from the vertebral canal under magnification, but since the cord tissue was quite friable, it got damaged. In this process, 12 tissue samples were wasted and the remaining 18 tissues were embedded in Parafin wax. Haematoxylin eosin and Glee's Silver stain were used to stain the preparation (3). These sections were studied under light microscopy. A temporal profile of SCR in *Calotus calotus* was evolved with the help of these sections.

RESULTS

Complete spinal cord transection (SCT) could be

*Corresponding Author

verified in 4 sections, where animals died 24 hours following transection. Nucleated red blood cells could

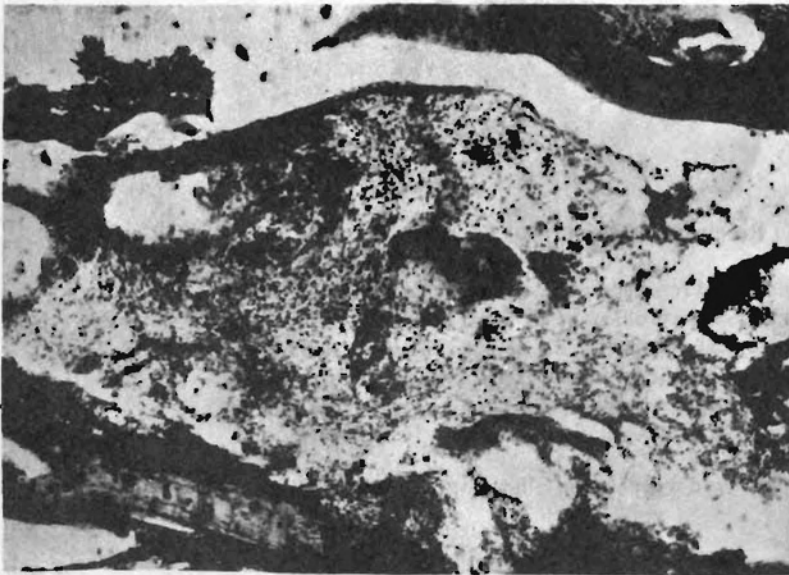

Fig. 1a : Fibrinoid necrosis with infiltration by neutrophils 48 hours following SCT. H and E stain $\times 125$

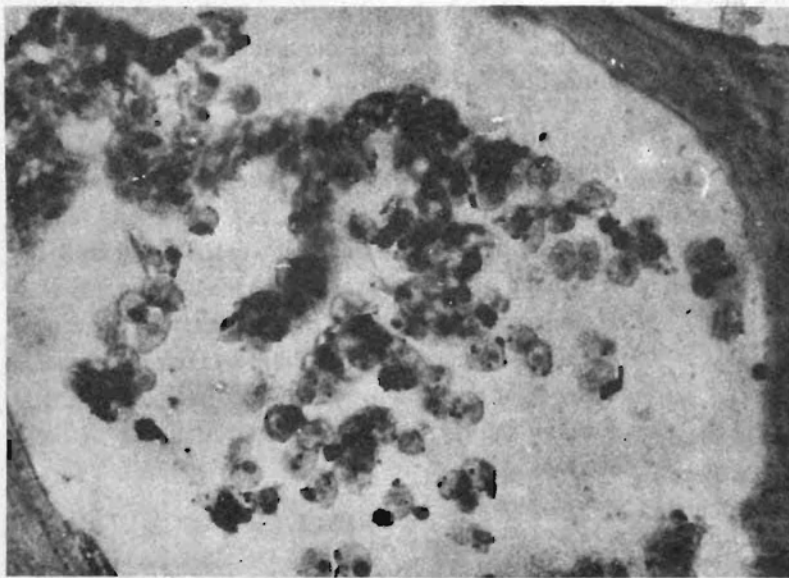


Fig. 1b : Foamy cells and histocytes as seen 1 week following SCT. H and E stain $\times 50$

be seen between the two stumps with evidence of retraction at both the ends. In 4 animals that died 48 hours following SCT, degenerative fibrinoid necrosis was noted. There was marked infiltration by the neutrophils (Fig. 1a). In 5 animals that died 1 week following SCT, there were areas of focal collection of macrophages. Foamy cells and histiocytes were also seen (Fig. 1b).

In 2 animals that died 1 month following SCT, neuroma formation was quite evident. There was proliferation of nerve fibres with intermingling of mononuclear cells and lymphocytes (Fig 1c). In three animals that died 2 months following SCT, sprouting nerve fibres could be seen bridging the gap between the two stumps. Chronic inflammatory cells were also seen at this stage (Fig. 1d).

DISCUSSION

The changes in the spinal cord are suggestive of regeneration between the two stumps. Axonal sprouting and their attempt to cross to the other side is all that can be commented upon. Though very tempting, it would be presumptuous to equate this process with regeneration, since true regeneration would mean approximation of the proximal end of an axon with the distal end of the same axon. The signal required for this ought to be

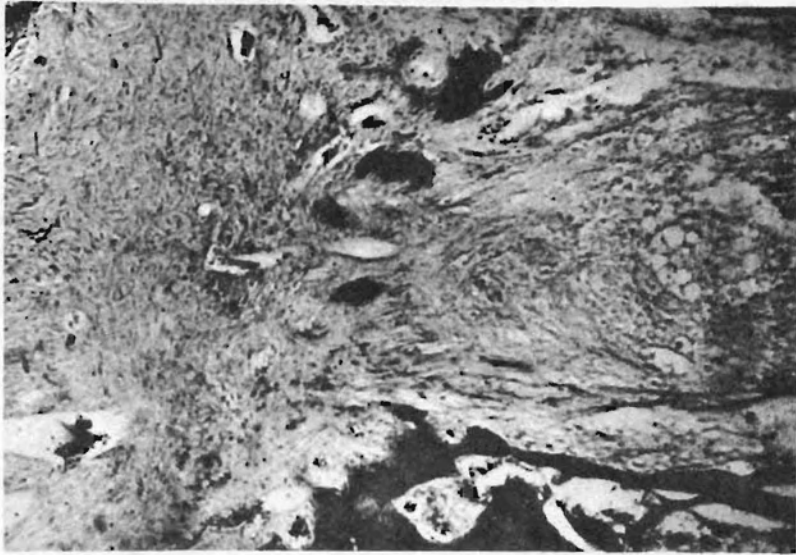

Fig. 1c : Neuroma formation is quite evident. Glees Silver stain $\times 50$

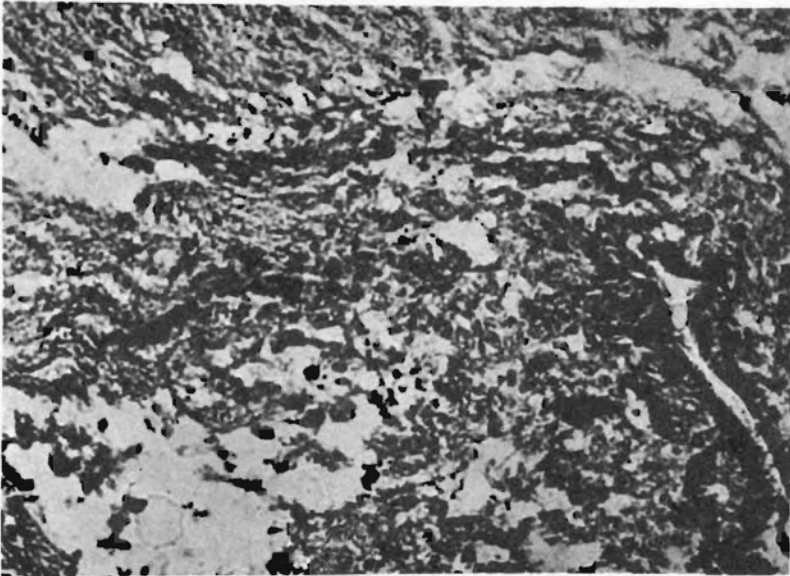


Fig. 1d : Chronic inflammatory cells are seen along with neuroma formation Glees Silver stain $\times 125$

chemotaxic. At the synaptic level, demonstration of synaptic connections would also mean true regeneration.

It is being gradually realised that synaptic connectivity may not actually translate itself into functional recovery (4). On the other hand, the recovery in the animal may not represent true SCR, but may actually be a result of spinal reflexes (5, 6). Spinal cat walks more or less normally within 48 hours of transection (7) which is too small a period for regeneration. In contrast to above mentioned reports, present study appears to support the contention that histological changes represent true regeneration leading to functional recovery.

Shaller et al (9) have demonstrated the presence of lymphocytes in their experimental allogenic nerve grafts in rats from 2nd to 4th week. They found that lymphocytes were distributed along the myelin Sheaths (9). From 4th week onwards, lymphocytes decreased in number. They consider it a sign of mild rejection. Presence of lymphocytes in the present material as late as 2 months, is difficult to explain.

REFERENCES

1. Windle, W. Regeneration in the central nervous system. Charles C Thomas, Springfield, Illinois, 1955.
2. Srivastava V.K. Functional recovery following reptilean (calotes calotes) spinal cord transection. *Indian J Physiol Pharmacol* 1992; 36(3) : 193-196.

3. Hasan Mahdi. Personal communication 1993.
4. Tandon PN. Therapeutic use of foetal neural transplants. Need for more basic Research. *Neurology India* 1991; 39: 1-2.
5. Bucy, Paul C. The human Neural Mechanism Controlling Skeletal Muscular Activity. In *Clinical Neurosurgery* vol 8 Ed. Mosberg, W.H. The Williams and Wilkins Co, Baltimore 1962; 1-31.
6. Shurrager P, Dykman RA. Walking spinal carnivores. *J Comp Physiol Psychol* 1951; 44 : 252-262.
7. Freeman LW. Experimental observations upon axonal regeneration in the transected spinal cord of mammals. *Clinical Neurosurgery* Vol 8 (The Williams and Wilkins Co. Baltimore) 1961; 294-316.
8. Cajal Ramon Y. Regeneration and degeneration of nervous system. Translated by May RM, (Oxford University Press, London), 1928.
9. Shaller E, Mailander P, Becker M, Walter GF, Berger A. Rejection of Allogenic nerve grafts in a genetic model of the rat. In *Peripheral nerve lesions* Ed Samii M. Springer Verlag, Berlin, 1990; 104-112.

